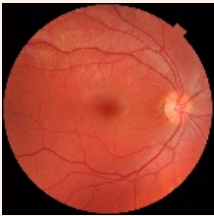

Retinal Morphometric Features

id	CDR	Tortuosity
1	0.482	0.423
2	0.491	0.654
3	0.521	0.534

Morphometric
Feature
Extraction



Colored Fundus
Photography

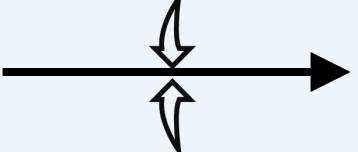
Image
Encoder

Image
Projection

- Higher than threshold
- Lower than threshold
- Revised matching
- Trainable
- Frozen

	F ₁	F ₂	F ₃	F ₄
F ₁	Higher than threshold	Higher than threshold	Lower than threshold	Lower than threshold
F ₂	Higher than threshold	Higher than threshold	Lower than threshold	Lower than threshold
F ₃	Lower than threshold	Lower than threshold	Higher than threshold	Lower than threshold
F ₄	Lower than threshold	Lower than threshold	Lower than threshold	Higher than threshold

Image-Image pair



	R ₁	R ₂	R ₃	R ₄
R ₁	Higher than threshold	Lower than threshold	Lower than threshold	Lower than threshold
R ₂	Lower than threshold	Higher than threshold	Higher than threshold	Lower than threshold
R ₃	Lower than threshold	Higher than threshold	Higher than threshold	Lower than threshold
R ₄	Lower than threshold	Lower than threshold	Lower than threshold	Higher than threshold

Text-Text pair

General Health Information (d=5)	Life Style (d=11)
Demographic Information (d=8)	Risk Factors (d=26)

AD
Risk Factors

Llama 3-1

The subject is 42 years old Caucasian male. The average total household of this subject is in between 30,000~60,000. The subject has 33 HbA1C, 1.2 HDL, 30 BMI, 131 systolic blood pressure,

Synthetic
Clinical Report

Text
Encoder

Text
Projection

Contrastive
Learning

Similarity
Matrix

T ₁
T ₂
T ₃
T ₄

	I ₁	I ₂	I ₃	I ₄
T ₁	Higher than threshold	Lower than threshold	Lower than threshold	Lower than threshold
T ₂	Lower than threshold	Higher than threshold	Lower than threshold	Lower than threshold
T ₃	Lower than threshold	Lower than threshold	Higher than threshold	Lower than threshold
T ₄	Lower than threshold	Lower than threshold	Lower than threshold	Higher than threshold

Original
Image-Text pair